

INFECTIOUS CORYZA

INTRODUCTION

Infectious coryza of chickens is an acute upper respiratory infection caused by the bacteria *Avibacterium paragallinarum*, known for causing decreased production leading to economic losses within affected flocks. Infectious coryza was first described in the early 1920s, but was not isolated and named until a decade later. The re-emergence of infectious coryza in commercial flocks within the United States from 2017–2019 challenged the diagnostic capabilities and resources available and drove the development of newer, faster testing procedures and better interventions.

CAUSE

Avibacterium paragallinarum is a gram-negative, non-motile bacteria appearing as short rods or coccobacilli when viewed under a microscope. Coryza has been characterized into nine serovars (groupings based on the antigens on the surface of the bacteria to which antibodies attach): A-1,2,3,4; B; C-1,2,3,4. The importance of serovars lies in knowing whether a commercial vaccine or an autogenous vaccine will cross-protect against field strains. Most recent cases of infectious coryza within the United States have been due to serovar C strains.

TRANSMISSION

Chickens are the natural host for coryza; cases of production loss, clinical symptoms, and/or mortality have been reported in all commercial strains of chickens. No other species of bird or mammal has been found infected with coryza, although certain species of birds and insects have been implicated as mechanical vectors (physically carry the bacteria on feet, feathers, etc.). All ages of chickens are susceptible to infection; birds that survive the infection often fully recover but persistently shed the bacteria as lifelong carriers. Due to the presence of carriers, elimination of the disease within a multi-age site is extremely difficult; whole site depopulation may be necessary if elimination of coryza is desired.

Avibacterium paragallinarum is shed from bird to bird in nasal secretions and can be transmitted by direct contact, airborne droplets, and/or contaminated drinking water and feed. Although coryza survives more than 4 hours in hot, dry weather, coryza can survive for more than 24 hours in colder, humid environments. Manure and equipment contaminated with coryza may transmit the disease from flock to flock if inadequate cleaning and disinfection is performed. Coryza may also be physically carried to an uninfected flock by mice, insects, workers' clothing and footwear, trucks and shared equipment, and from close contact with backyard birds or affected flocks.

INCUBATION PERIOD

Clinical signs are typically seen within 1–3 days post-exposure. The bacteria spreads rapidly between birds within the same air-space and with physical contact; in multi-house sites with a common egg-belt and/or walkway system, clinical signs may be seen in all houses within days/weeks.

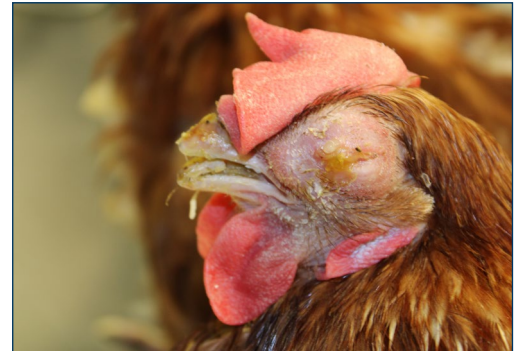

Figure 1. A hen showing typical swelling of the sinuses due to infectious coryza. Photos: Mohamed El-Gazzar, Iowa State University.



Figure 2. Swelling around the eye along with nasal discharge in an affected hen. Photo: Hy-Line North America.



CLINICAL SIGNS/SYMPTOMS

Infectious coryza is characterized by upper respiratory symptoms along with a significant drop in feed and water consumption. Respiratory symptoms typically include swelling under and around the eyes, nasal and ocular discharge, and sneezing/rales. In some birds, swollen wattles may be seen (Figures 1, 2). Airsacculitis has been noted in affected broilers. Birds are often depressed with less activity and vocalization; diarrhea may be seen due to birds being feverish and off-feed. Hens that do not recover and regain their appetites rapidly may have regressed/shrunk reproductive tracts as they go out of production. Co-infections with other diseases (ILT, IBV, MG, FP, *E.coli*, etc.) often increases the severity of clinical signs seen in affected flocks.

In laboratory situations, individual birds with no other complications typically recover within 14 days of exposure; individual chickens in the field typically recover in 3–6 weeks. Outbreaks in flocks may last between 4–10 weeks, with production drops ranging from 10–60% depending on age, health status, other diseases present, and type/size/structure of the house.

DIAGNOSIS

Avibacterium paragallinarum can be readily detected in nasal and ocular secretions via bacterial culture or PCR. Hemagglutination inhibition (HI) may be useful to identify serotype for vaccine selection and/or autogenous vaccine production. Ideal samples are a) tracheal and/or oropharyngeal (mouth cleft) swabs, b) fresh lungs and/or swabs of lungs, or c) whole fresh heads. Keep samples cool (not frozen) and ship with cold-pacs.

INTERVENTION STRATEGIES

Prevention and Management

- Practice good cleaning and disinfection protocols when moving between flocks and/or houses.
- Equipment, clothing, hands/hair/skin, and footwear can carry bacteria to an uninfected flock.
- Site-specific clothing and footwear may help reduce risk of the introduction of infectious coryza and other harmful diseases.
- Obtain replacement birds from uninfected flocks. If moving birds into an infected multi-age site, vaccinate with an appropriate vaccine with the second vaccination at least two weeks prior to move.
- For all-in-all-out sites, focus on cleaning and disinfecting between flocks: wash, dry, disinfect, +/- fumigation.

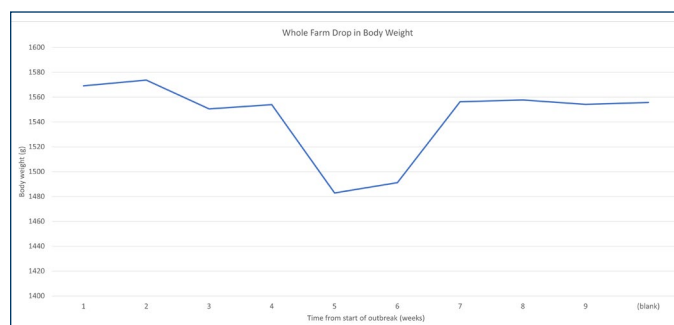


Figure 3. Effect on body weight by strain due to infectious coryza following outbreak on a commercial farm with multiple strains of white-egg layers present.

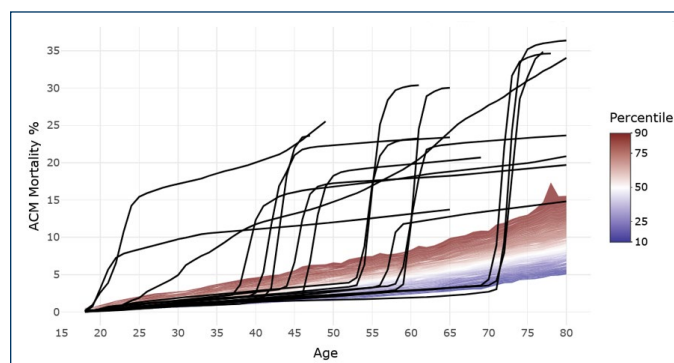


Figure 4. Mortality due to infectious coryza. Black lines represent coryza-positive flocks. Colored area in background represents control (non-infected) flocks for comparison.

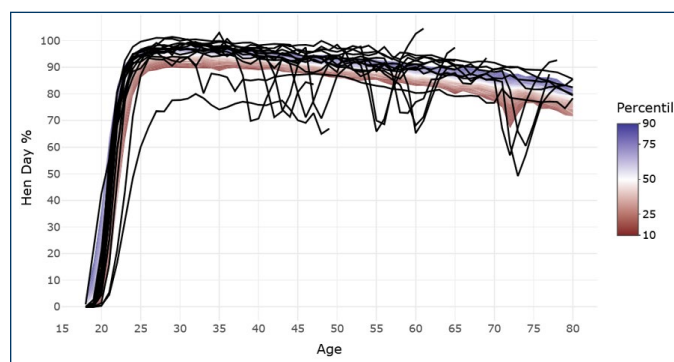


Figure 5. Effect due to infectious coryza on hen-day production. Black lines represent coryza-positive flocks. Colored area in background represents control (noninfected) flocks for comparison.

Vaccination and Treatment

- Inactivated bacterin vaccines are commercially available. Autogenous bacterin vaccines can be created from bacteria isolated from the same farm or an epidemiologically connected site.
- Vaccine administration is via individual bird injections; site of injection is ideally in the breast muscle but may also be given subcutaneously in the leg fold (not recommended in cage-free operations).
- The oil-adjuvanted bacterin vaccine must be given twice for full efficacy. These vaccines may cause a high level of tissue reaction; as such, giving the vaccine at approximately 8 weeks and 12 weeks of age is recommended to provide the best protection prior to lay with the least amount of impact on birds coming into production.
- The first vaccine may need to be administered earlier in the pullet period due to exposure on multi-age pullet farms or dense poultry areas.
- The vaccine must match the serotype (A, B, or C) isolated from the infected birds; minimal to no cross-protection is developed by a non-matching vaccine. Specific serovars (i.e. C-1) may be necessary to have adequate level of protection against the field challenge.
- Treatment options are with antimicrobials such as chlortetracycline (CTC) under veterinary supervision. A wider range of antimicrobials may be available to treat pullets.
- Supportive care can also be used (vitamins, electrolytes, midnight feedings, higher density diets, cooler house temperatures, vaccinate in the face of the outbreak).

REFERENCES

1. Blackall, Pat J. and Matsumoto, M. Chapter 20: Infectious Coryza. Diseases of Poultry. 13th Edition. Ames: Wiley-Blackwell, 2013. Print.
2. Gallardo, R.A et. al. Infectious Coryza: Persistence, Genotyping, and Vaccine Testing. Avian Diseases 64:157-165, 2020.
3. Soriano-Vargas, Edgardo. Merck Veterinary Manual. Overview of Infectious Coryza in Chickens. Retrieved from <https://www.merckvetmanual.com/poultry/infectious-coryza/infectious-coryza-inchickens>.

DISEASES THAT MIMIC INFECTIOUS CORYZA

Other diseases that may cause similar symptoms to infectious coryza include: mycoplasmosis (MG), infectious bronchitis, fowl cholera, and infectious laryngotracheitis. Highly pathogenic avian influenza (HPAI) may present with similar symptoms at the beginning of an outbreak; however, mortality from HPAI will typically continue to increase, with overall mortality numbers much higher than seen with infectious coryza.

DISINFECTION

Avibacterium paragallinarum is readily killed by UV light, heat, and most disinfectants. Moist environments (water, manure) may prolong survival of the organism, highlighting the importance of properly cleaning and disinfecting clothing, equipment, etc.

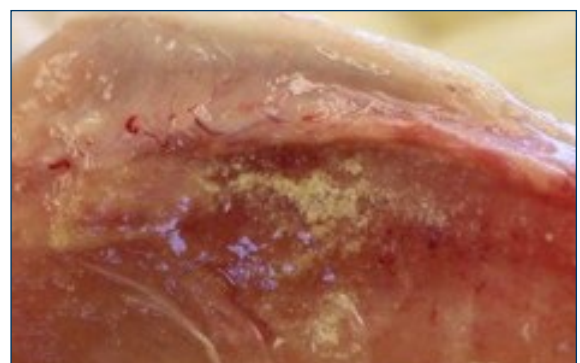
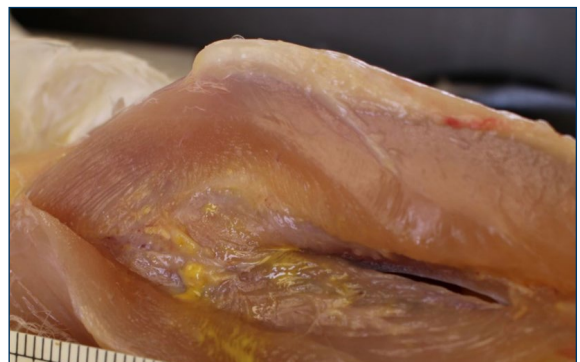

Figure 6. Vaccination with oil-adjuvanted coryza vaccines may cause tissue trauma, leading to decreased weight gain and decreased uniformity in pullet flocks. Photos: Dr. Sherill Davison.



Hy-Line International | www.hyline.com

